

UK CPN case
Dr Suvarna

28 female

Found deceased.

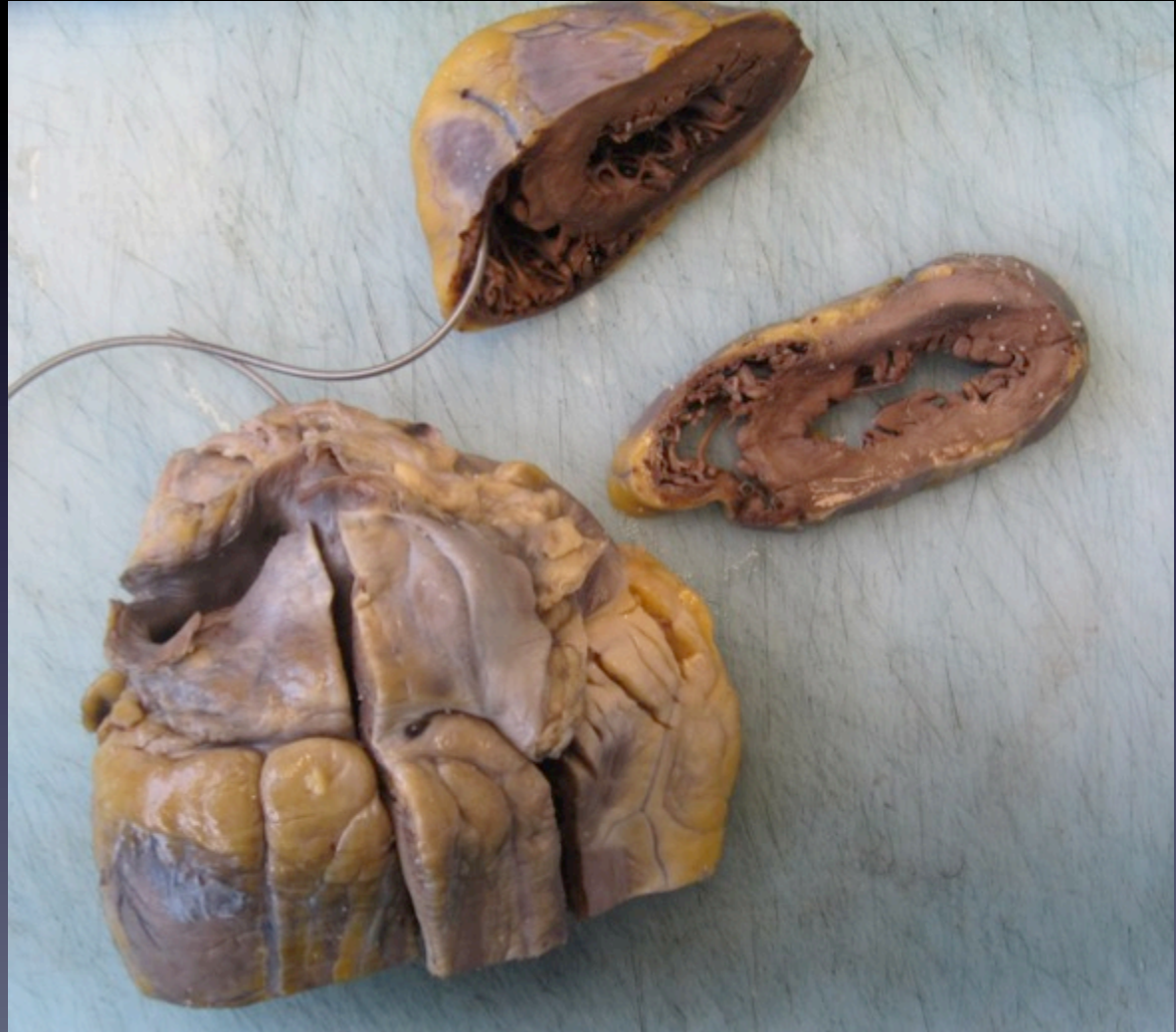Previous dual chamber pacemaker for congenital heart block.

No other history.

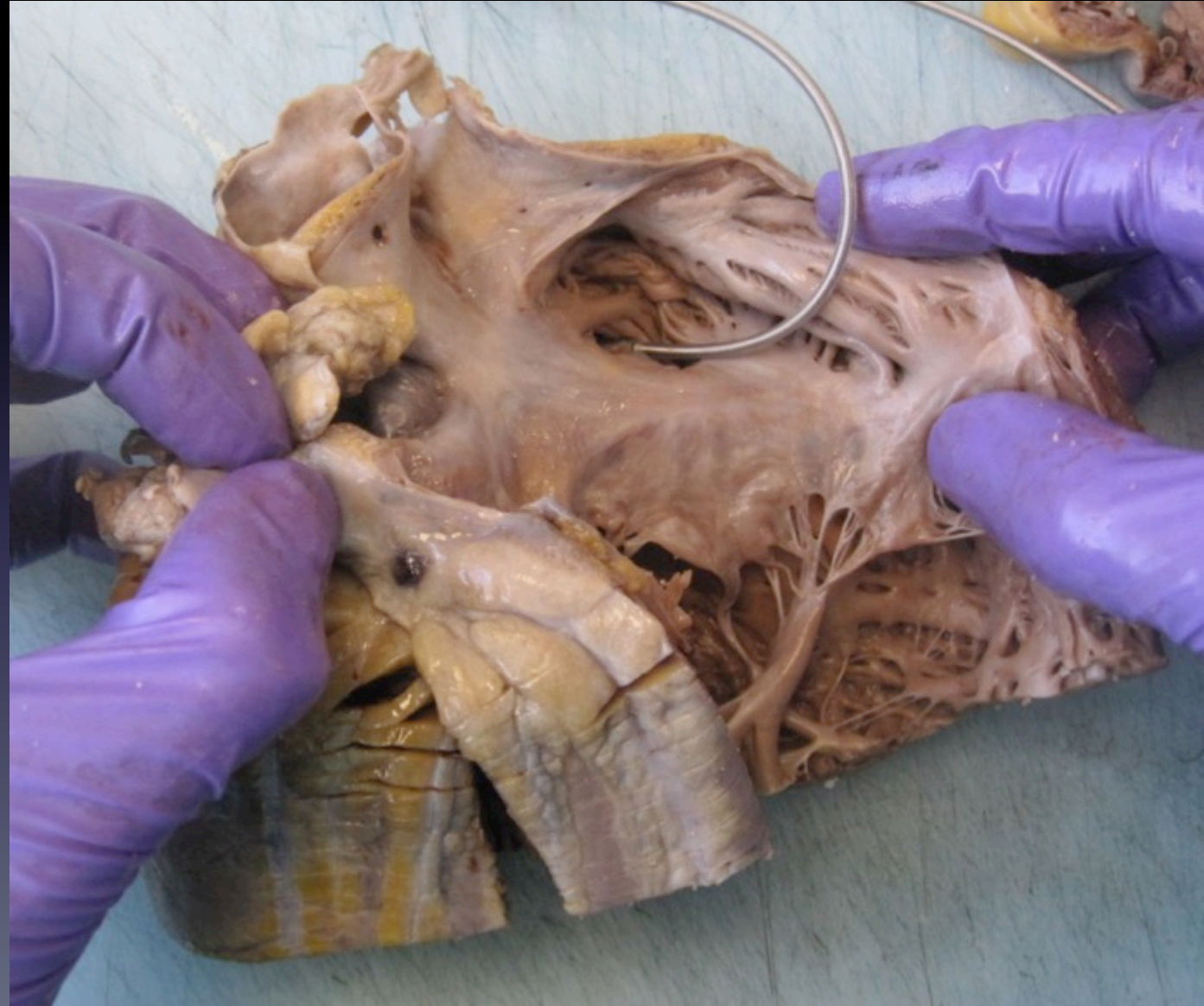The heart appeared enlarged, 415 g.

The sample has been opened to check for correct position of the 2 electrodes/leads.

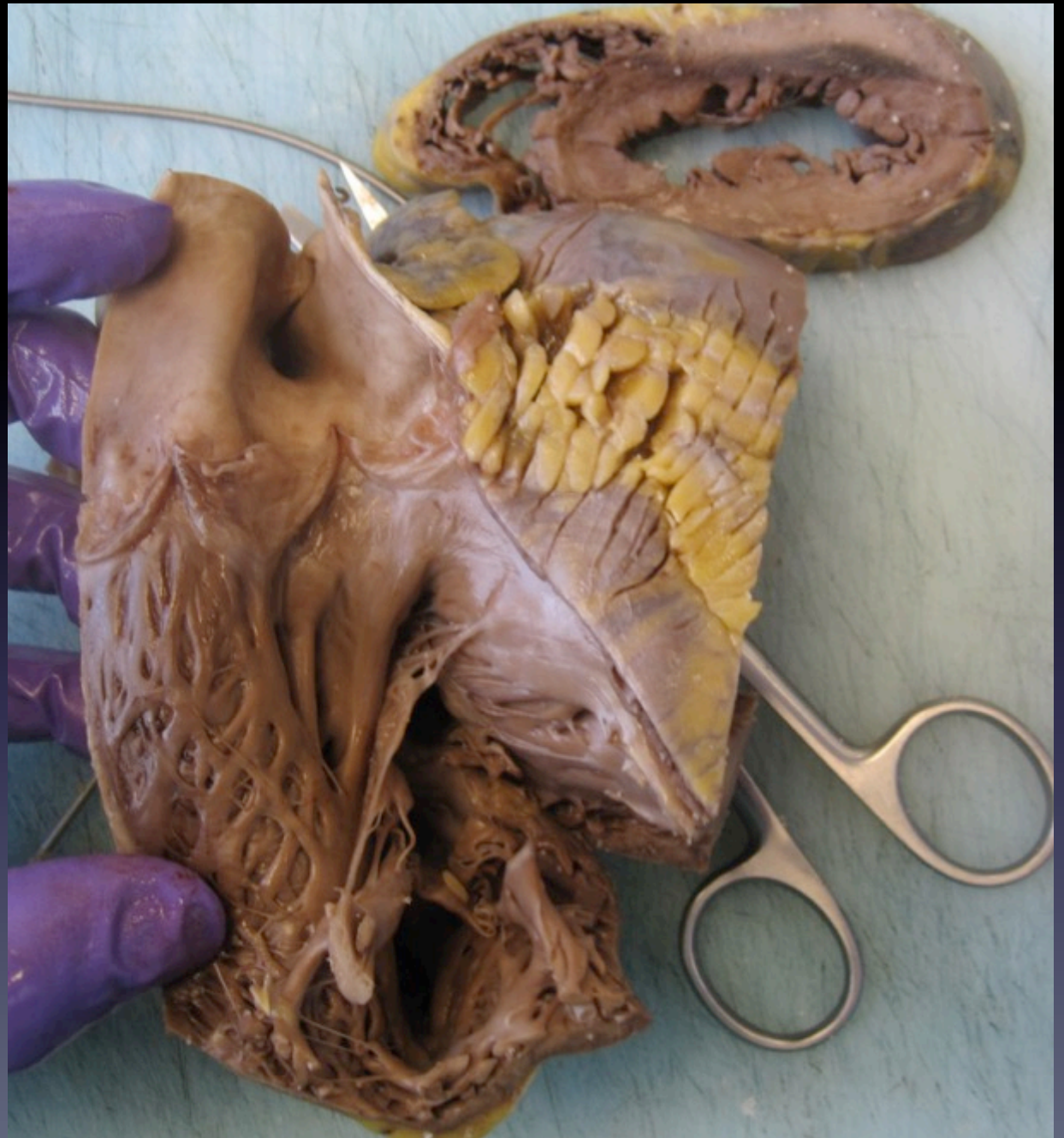No infective endocarditis



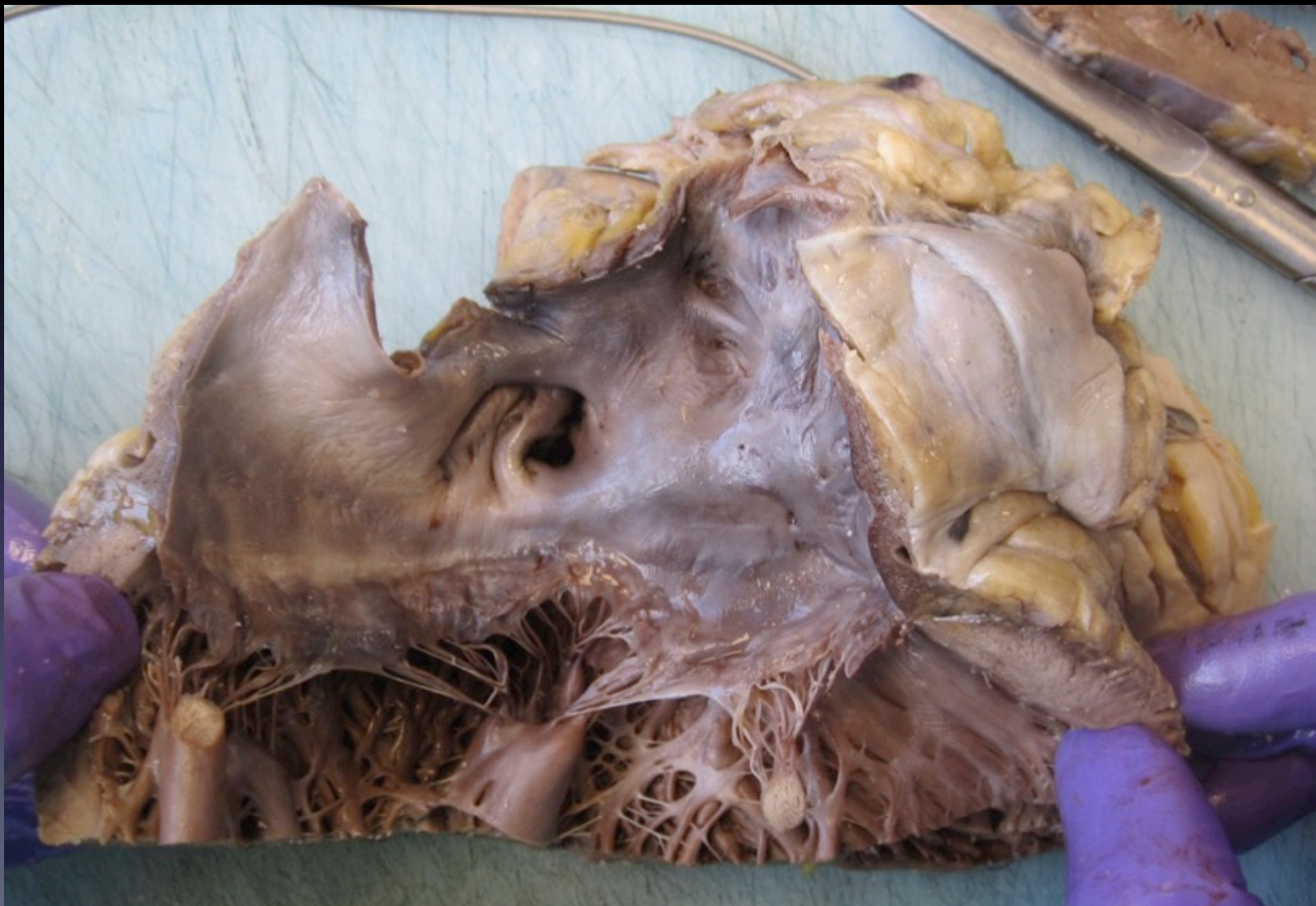R atrium view



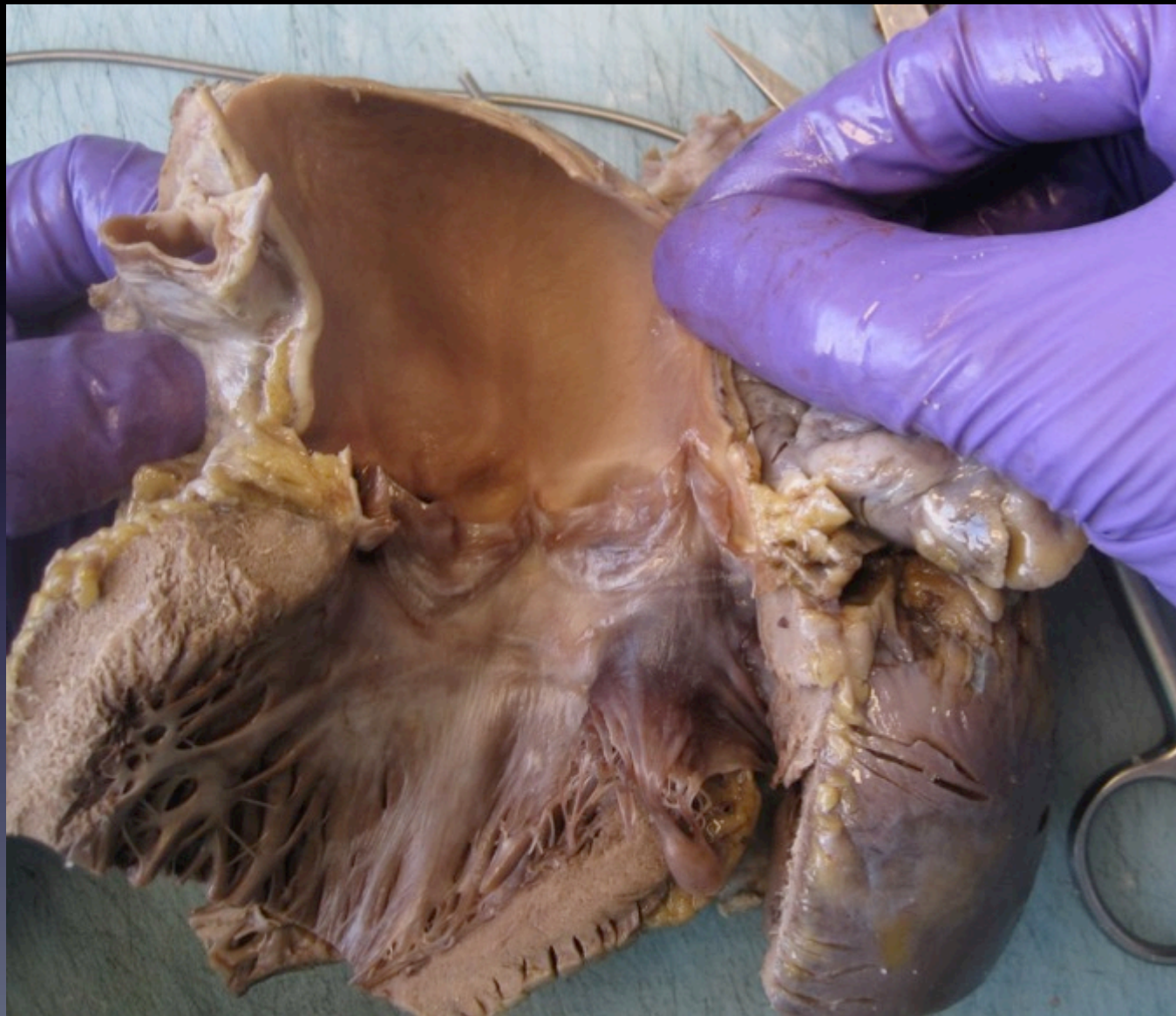RV outflow



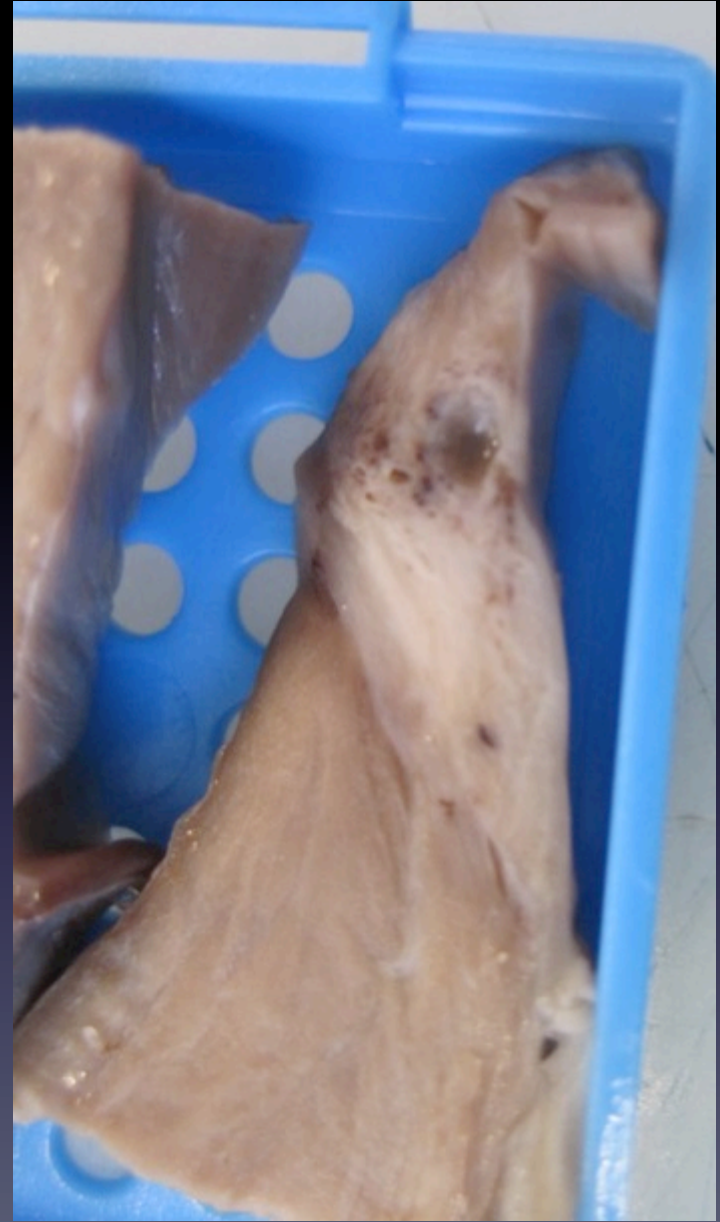L atrium



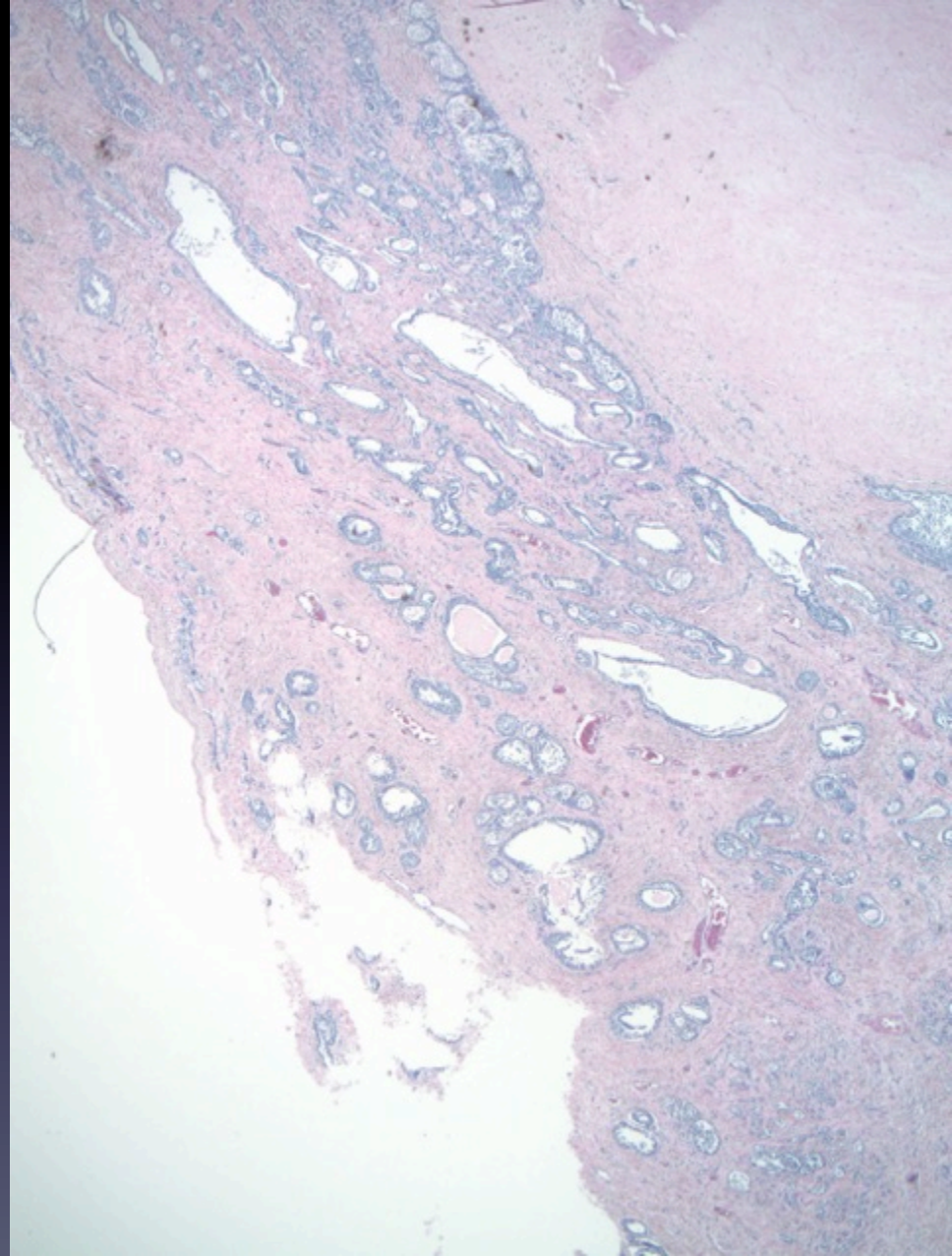
LV outflow and AV



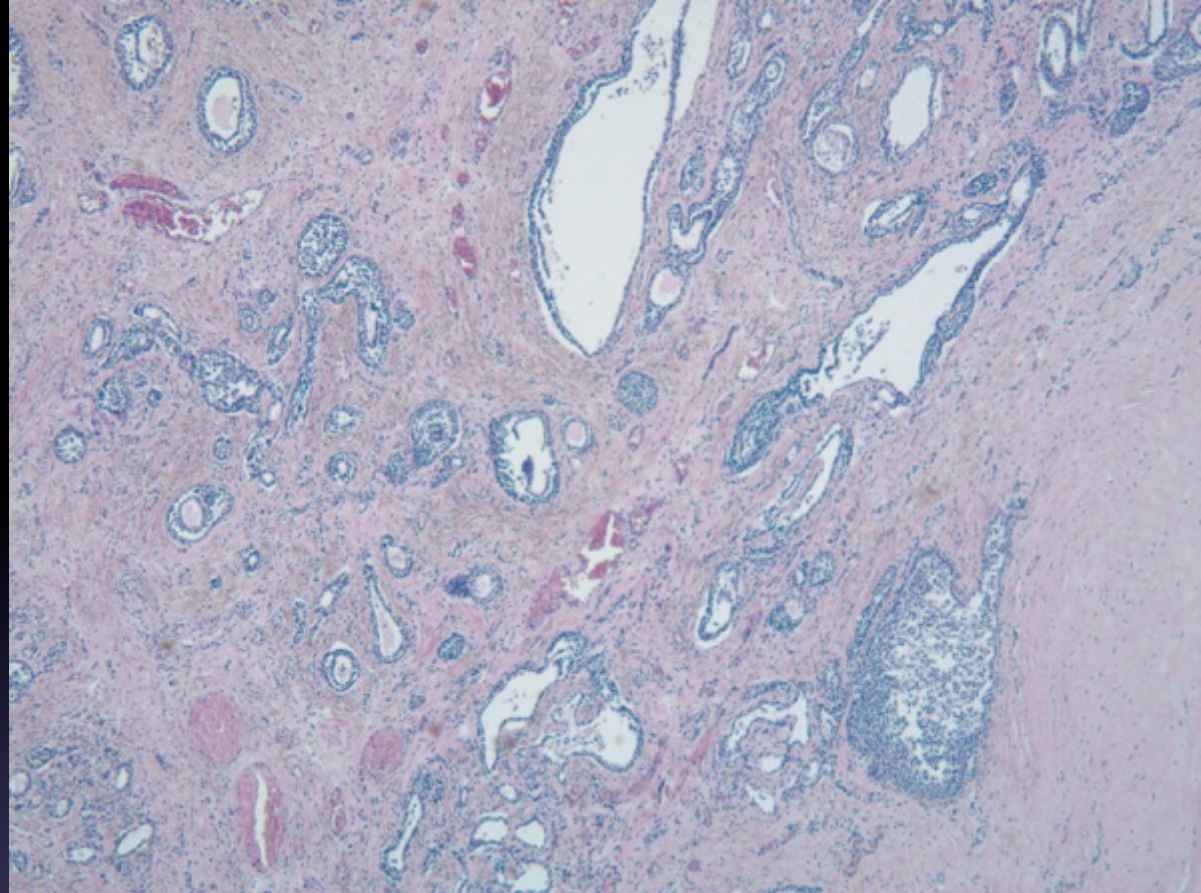
Section through AV Node and septum



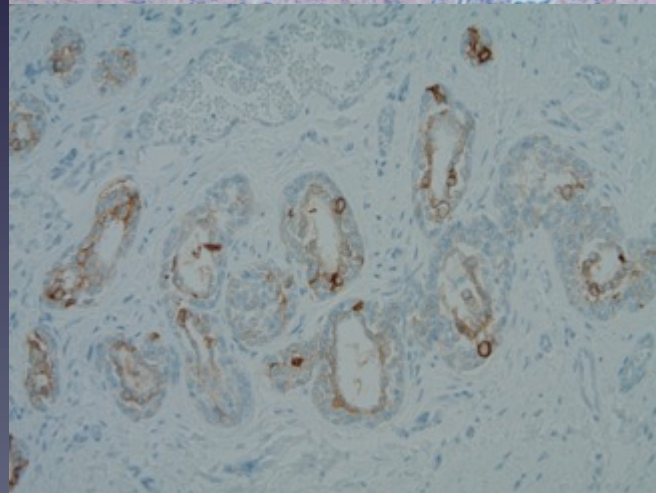
Section through the AVN



High
magnification
of AVN gland
spaces



Epithelial as
seen with
BerEp4+



Diagnosis

Cystic atrioventricular node tumour