

UK CPN case

Dr Suvarna

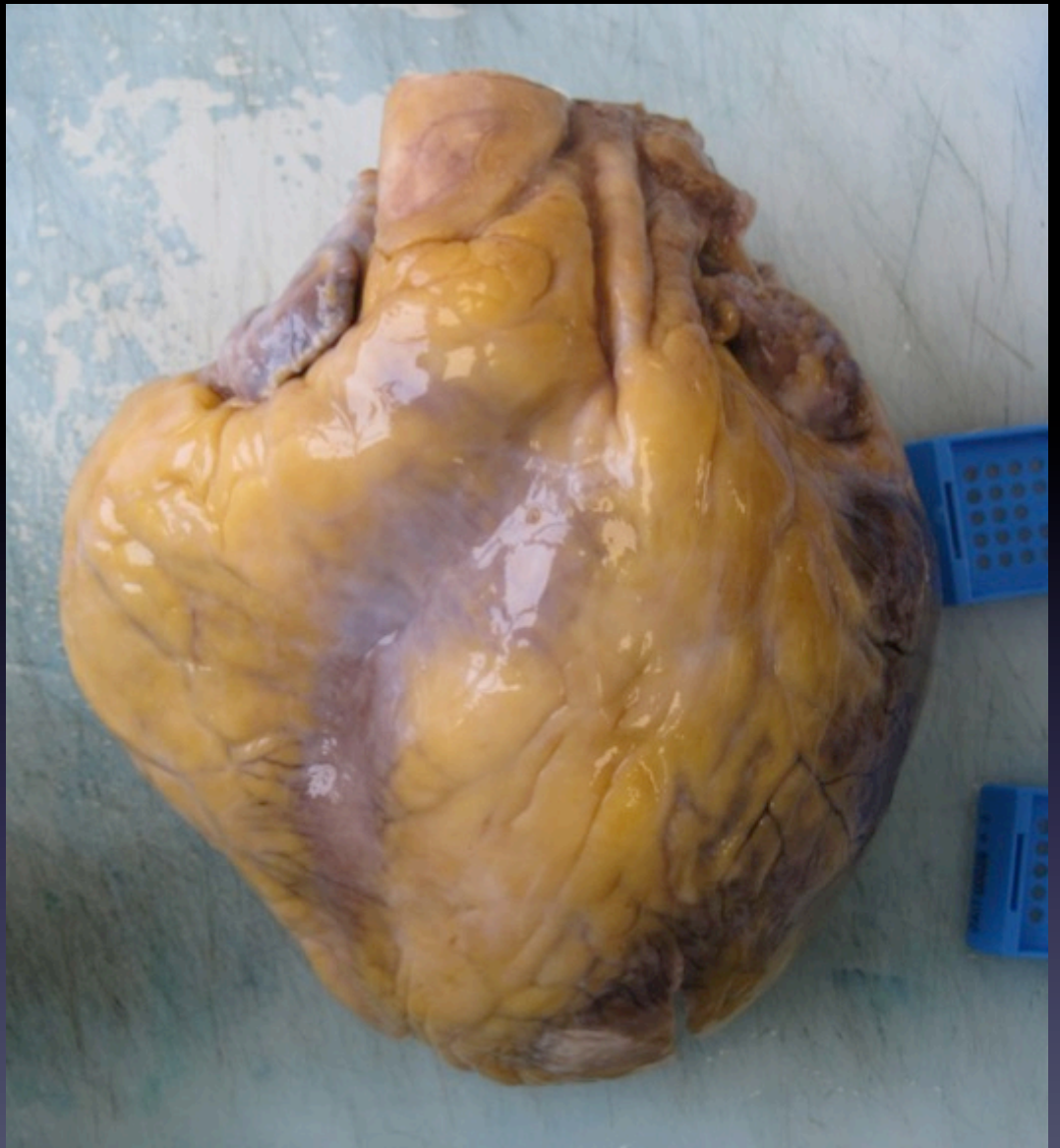30 year old male

Some syncopal events during exercise

Sudden death

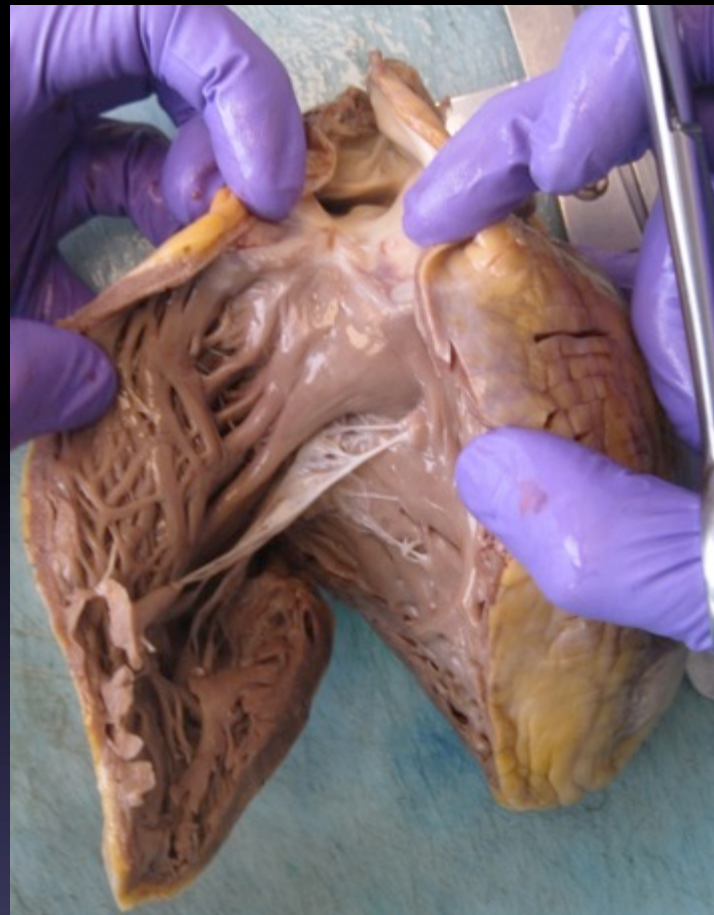
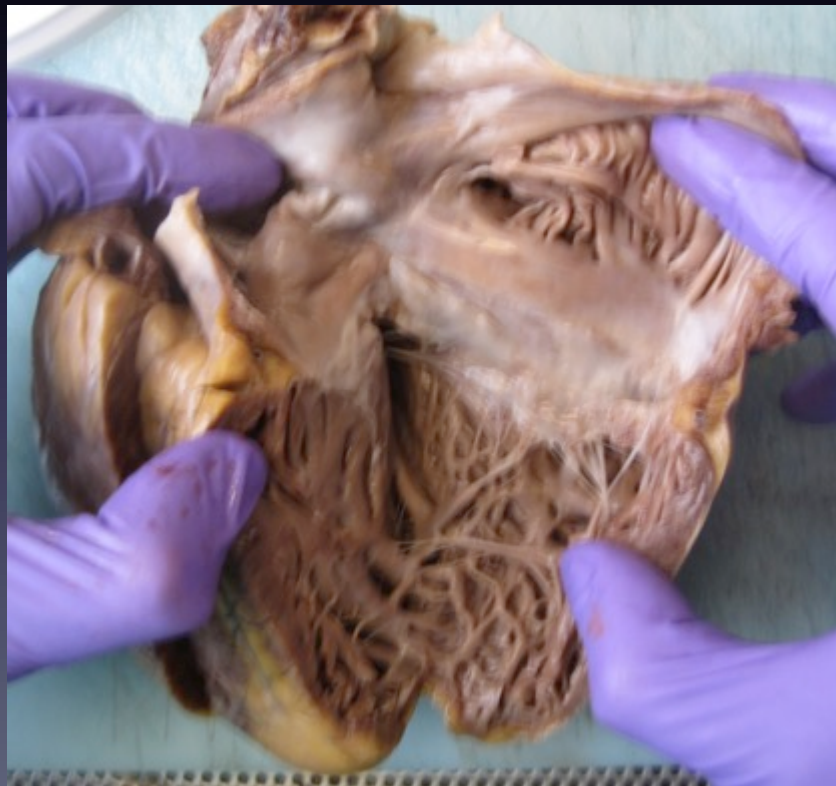510 g  
(expected 360-420 g)

No anatomical  
abnormality  
externally



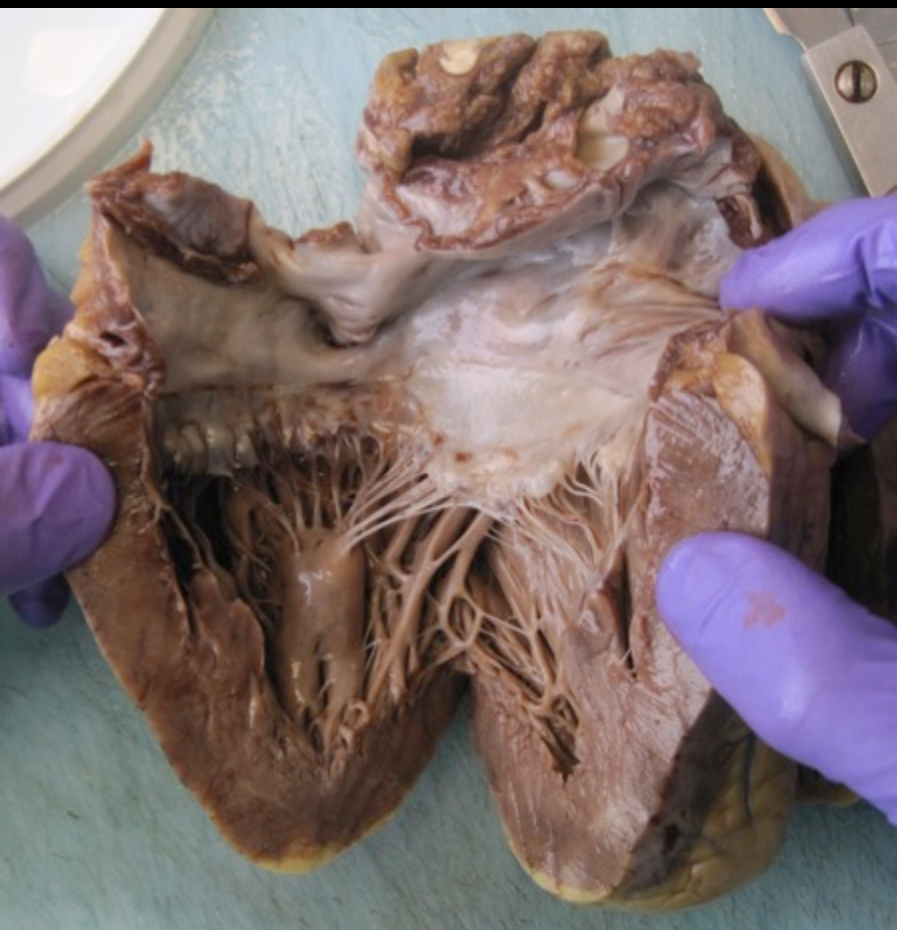RV

RA

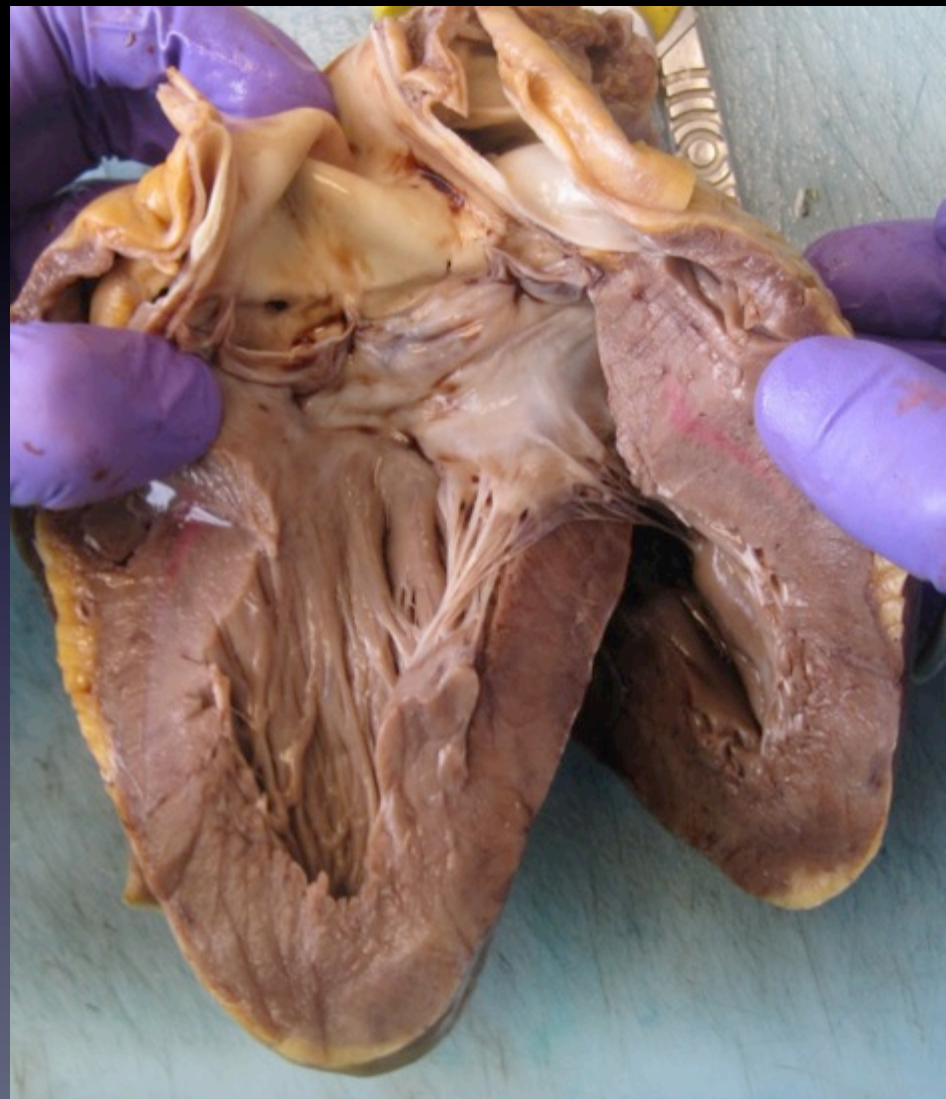



LA



LV

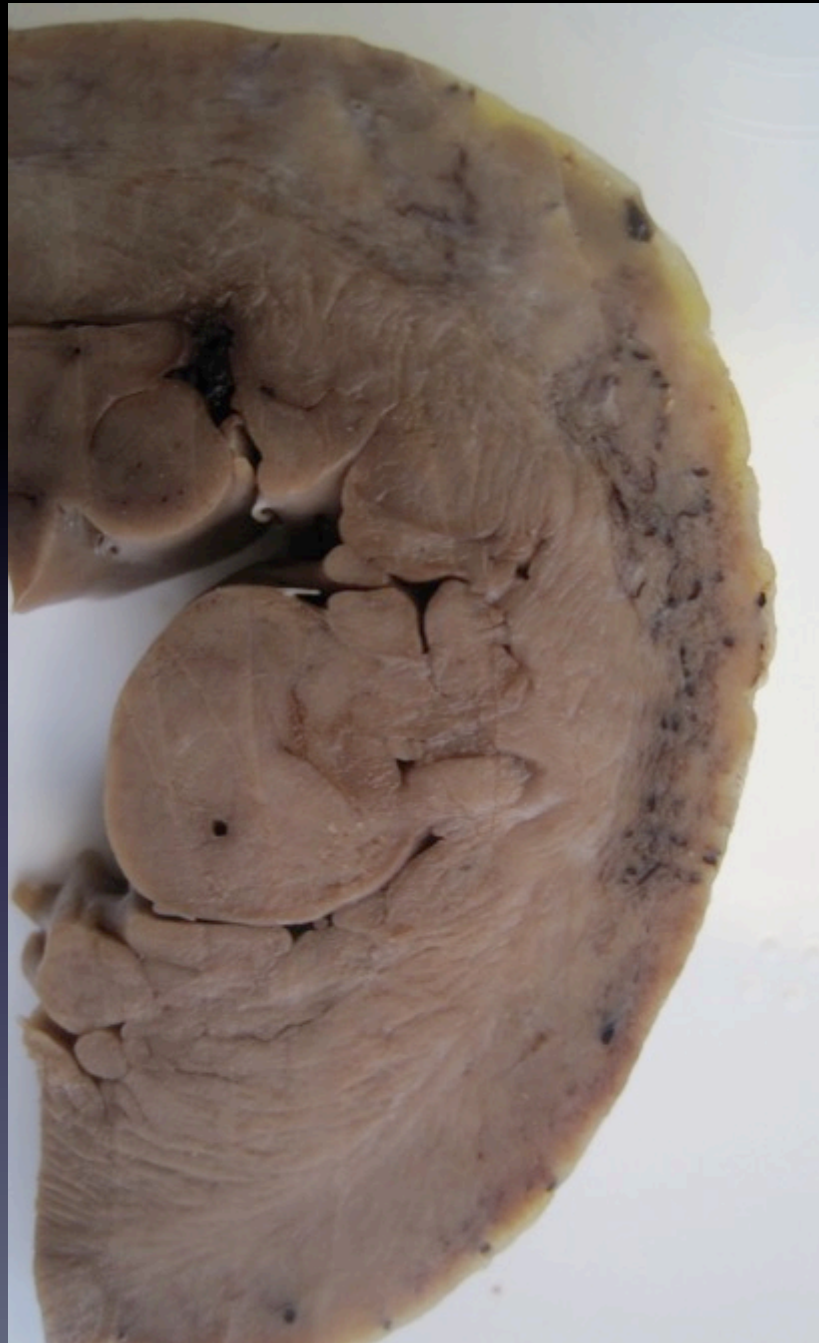

Transverse view  
RV, septum  
& LV

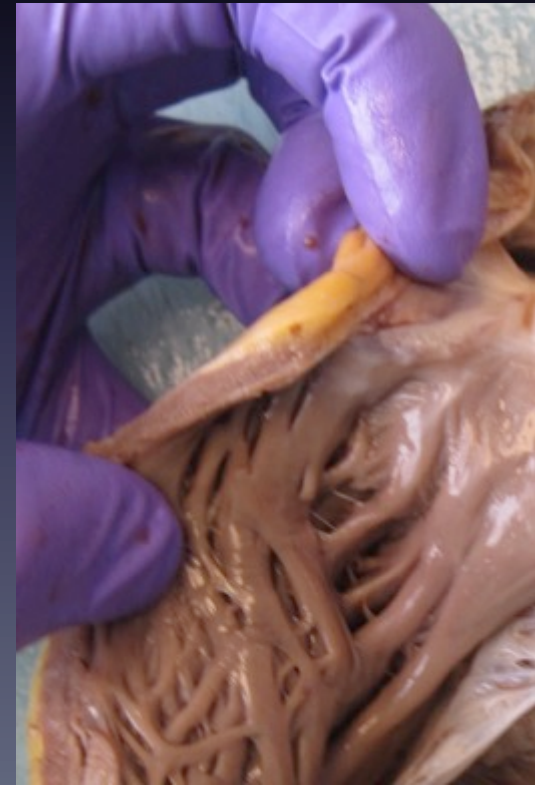



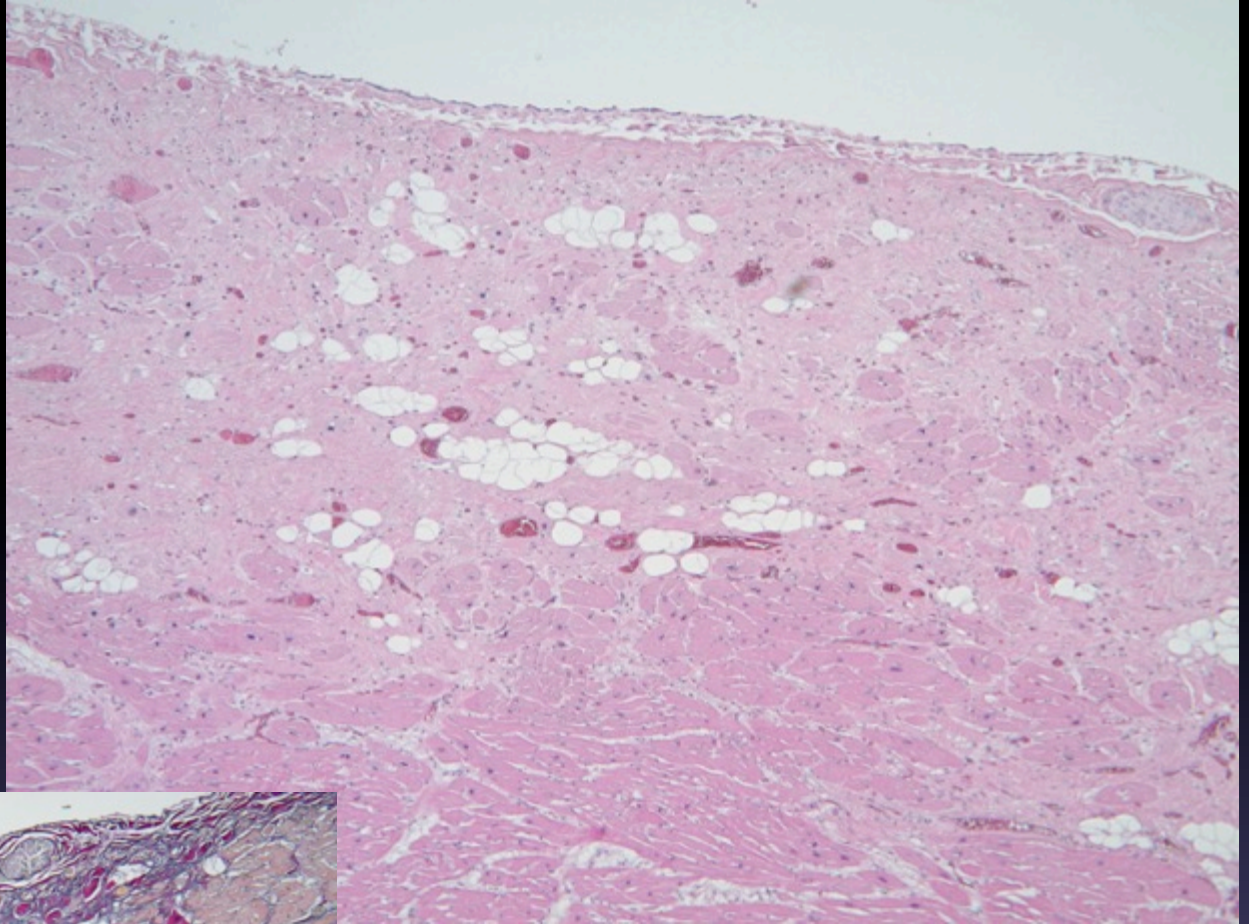
LV view  
Scarred area  
lateral wall  
LV



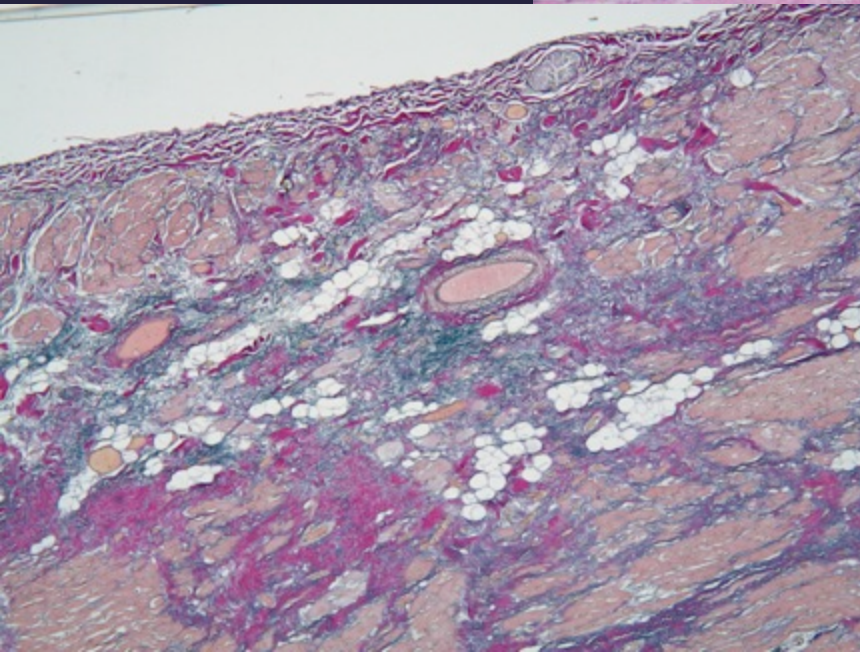
RVOT view



LV  
H/E view

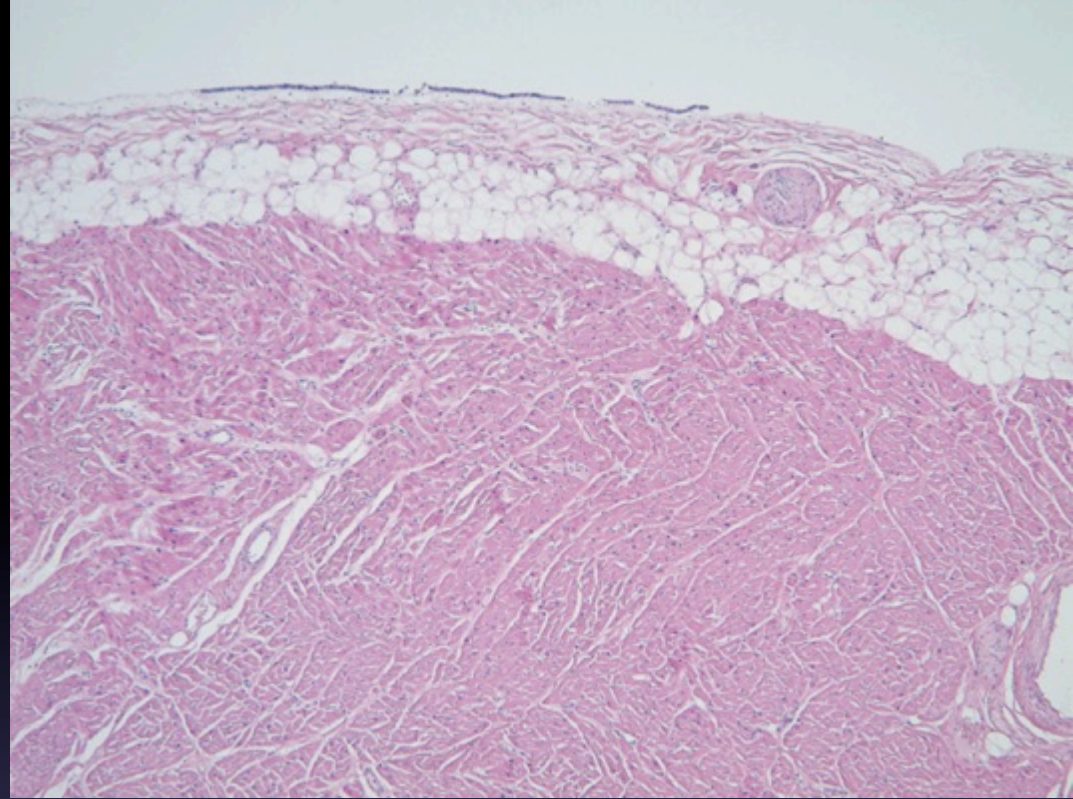


EVG view  
showing  
marked  
fibrosis and  
some fat

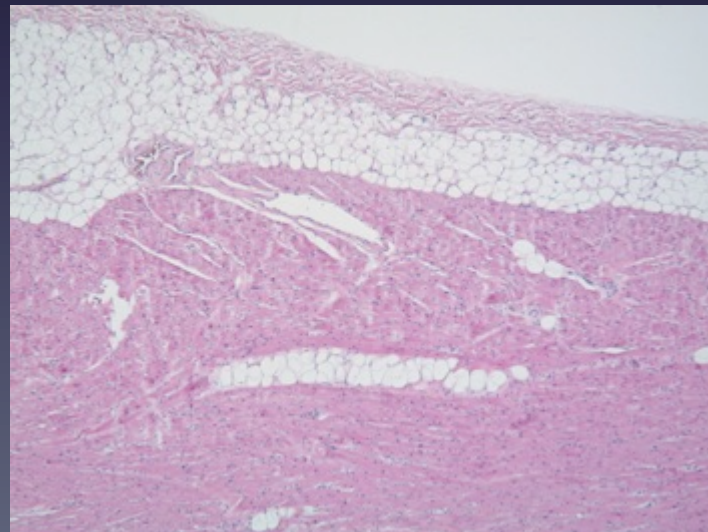




LV view



RV view





The heart showed only left ventricle fibrosis and fatty tissue replacement in the periphery of the free wall.

No family history of sudden deaths.

Likely left ventricle variant of arrhythmogenic cardiomyopathy. Note no real changes in right ventricle.

Genetics awaited.