

UK CPN case  
Dr Howitt

36 year old with lupus

# 36 year old with lupus

- 36 year old diagnosed in 2015 with lupus (possible Sjögren's/SLE overlap)
- Symptoms: cutaneous vasculitis, mouth ulcers, sicca symptoms, arthralgia, myalgia, fatigue, pitting oedema lower legs, livedo reticularis)
- Treated with steroids and chloroquine
- Good response

# 36 year old with lupus

- In May/June treated for cellulitis lower legs with Teicoplanin
- Discontinued because of suspected drug reaction (lip swelling, erythematous rash)
- Admitted on 13th June via GP, fever, unwell, dizziness and nausea over the preceding 2 days. An erythematous rash had appeared on the day of admission.

# 36 year old with lupus

- CT on admission: mediastinal, neck and axillary lymphadenopathy, large pleural effusion, hazy opacity in lungs, ascites
- Echo: mild concentric LVH
- Severe hypoalbuminaemia
- Blood cultures negative
- Tachycardia and pyrexia

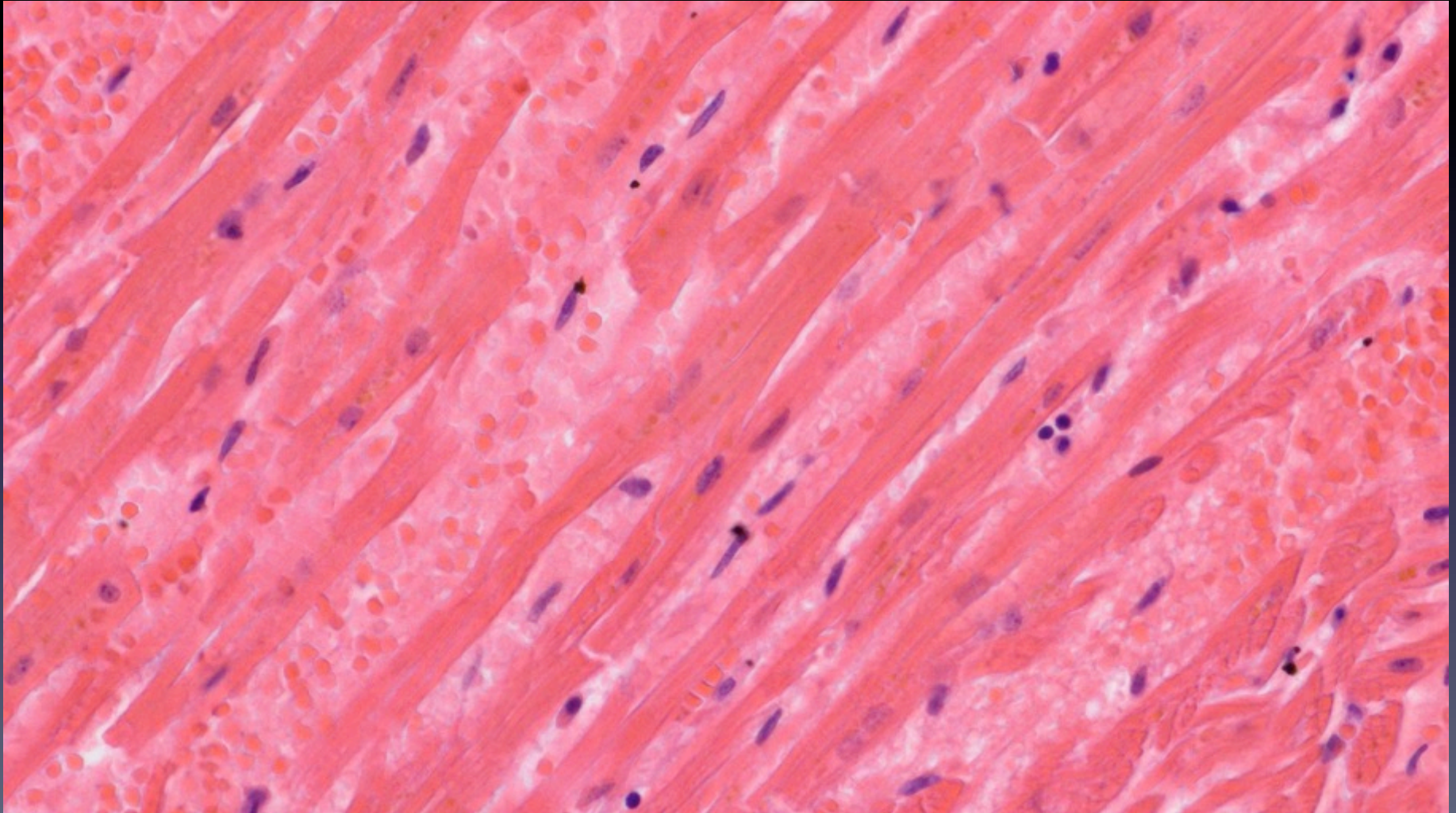
# 36 year old with lupus

- Arrested on ITU with asystole
- PM findings: large pleural effusions, ascites, chocolate brown heart, lymphadenopathy (neck, axilla, mediastinum), congested lungs
- Histology: reactive lymph nodes, extremely congested heart but no myocarditis and no disarray, autolysed liver but no evidence of liver disease

# 36 year old with lupus

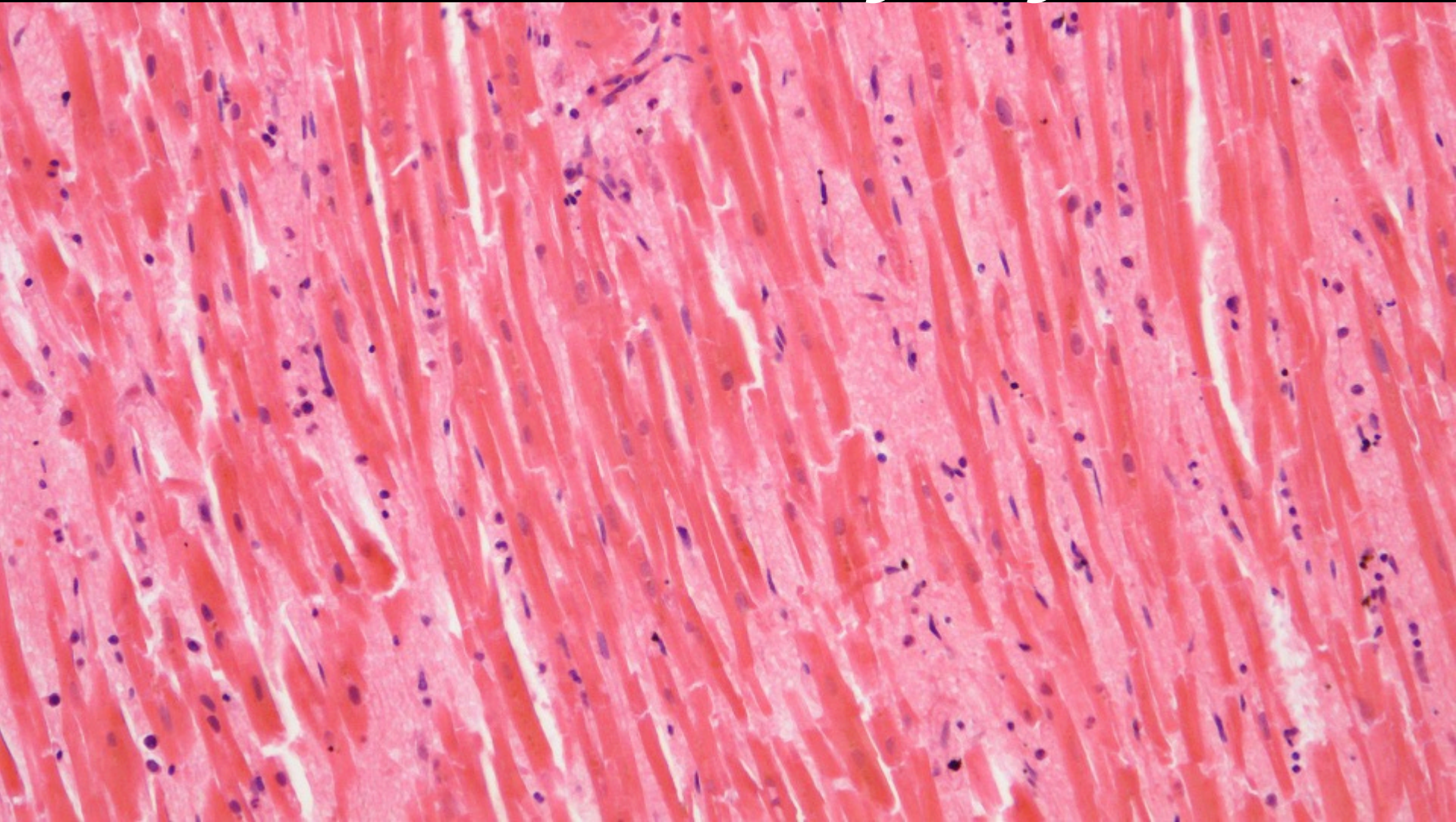
- Tissue and fluid culture (heart, pleural effusion, spleen, lymph nodes) all negative

# Congested heart



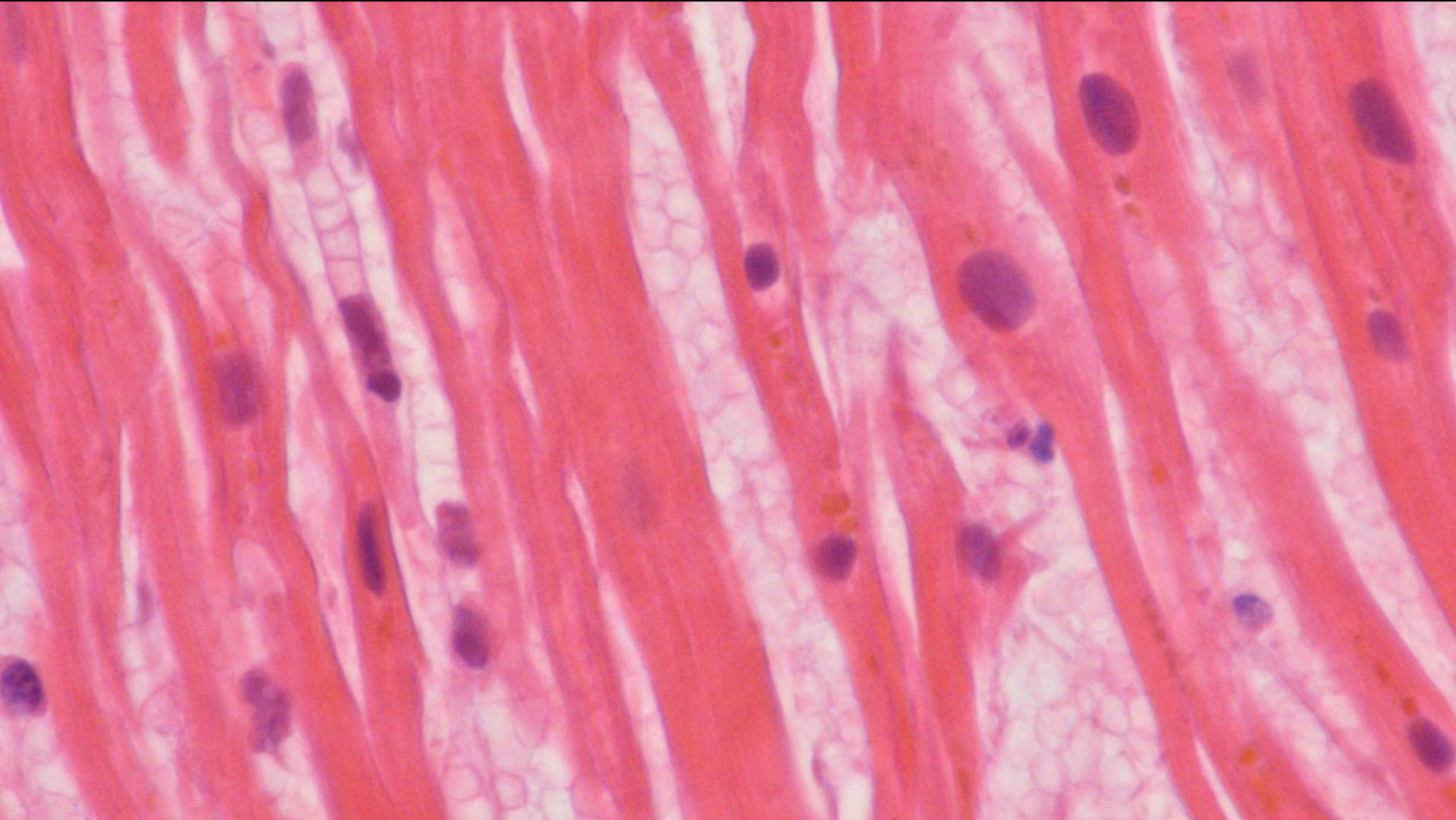


# Thin cardiomyocytes

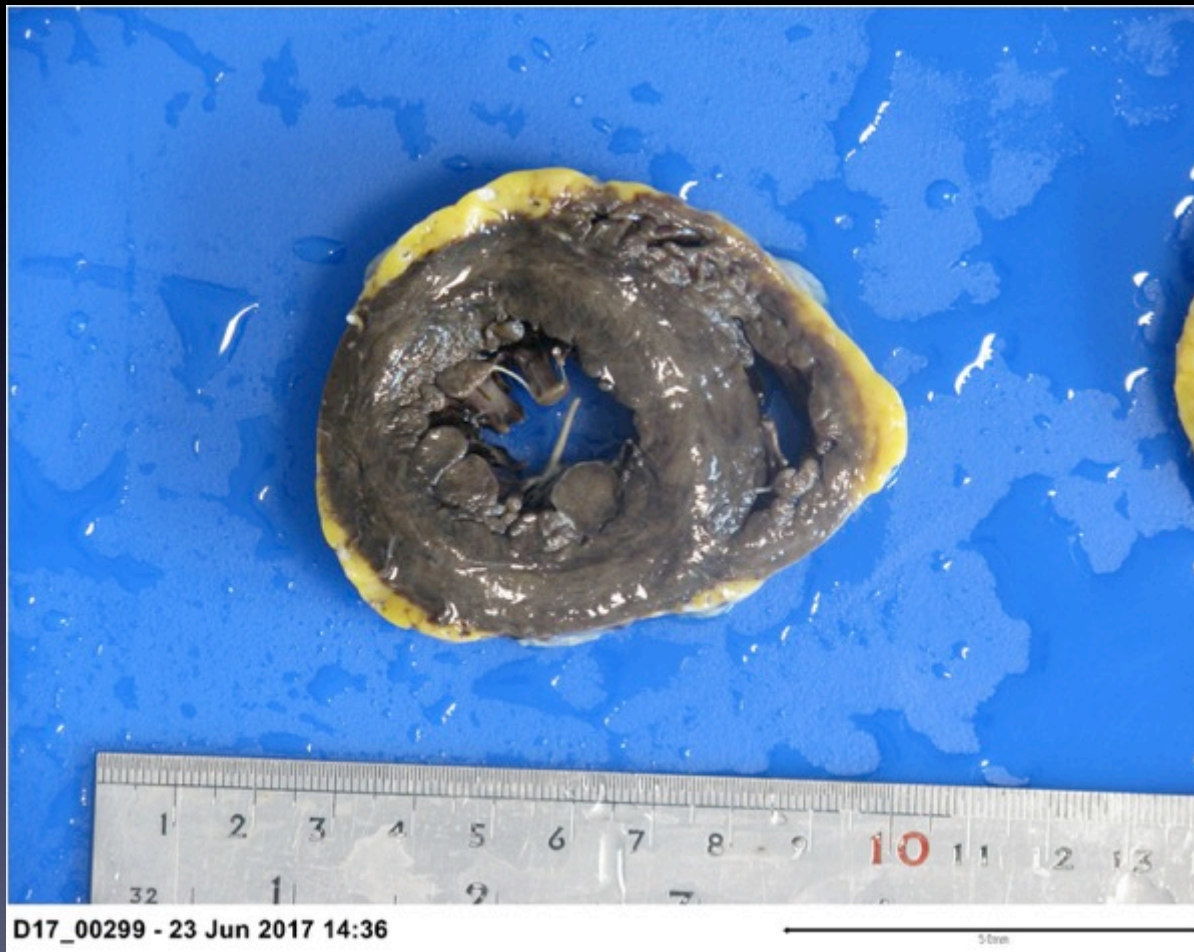



# Thin cardiomyocytes



# Brown heart / ?LVH



# Questions

- Are the cardiomyocytes abnormally thin or do they just look like it because of congestion?
- Is there a link between SLE and sudden cardiac death?