

Case 1 for UK Cardiac Network

Dr Lizzie Webb

Leicester Royal Infirmary

History

- 53 year old male
- PMHx: BPH, Nil else to note (no known cardiac disease).
- Recent history of flu like illness and cough.
- Two day history of vomiting and diarrhoea.
- Collapsed on toilet.
- Bystander CPR. Ambulance arrived, attempted shocks etc.

External Examination

- ECG stickers and defib stickers.
- Nil significant.

Internal examination

- CVS

Heart weighed 590g, gross pallor of left ventricle.

50% atheroma proximal LAD

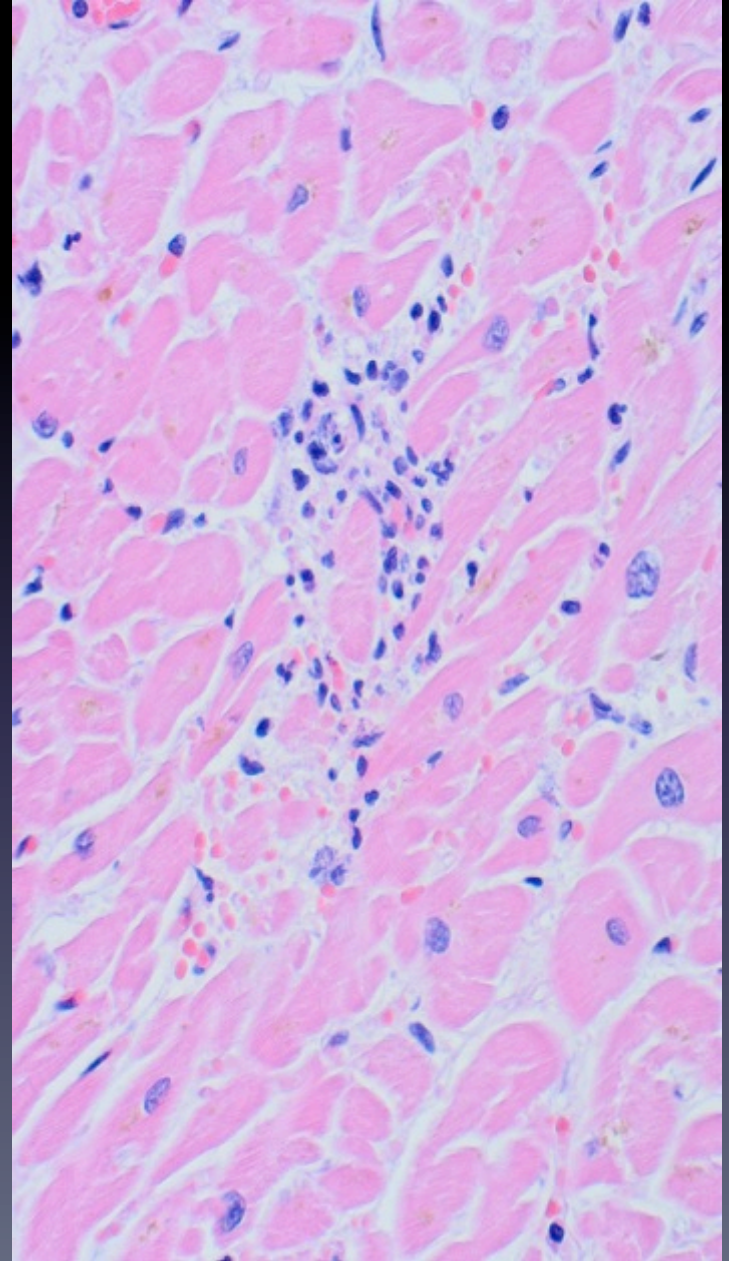
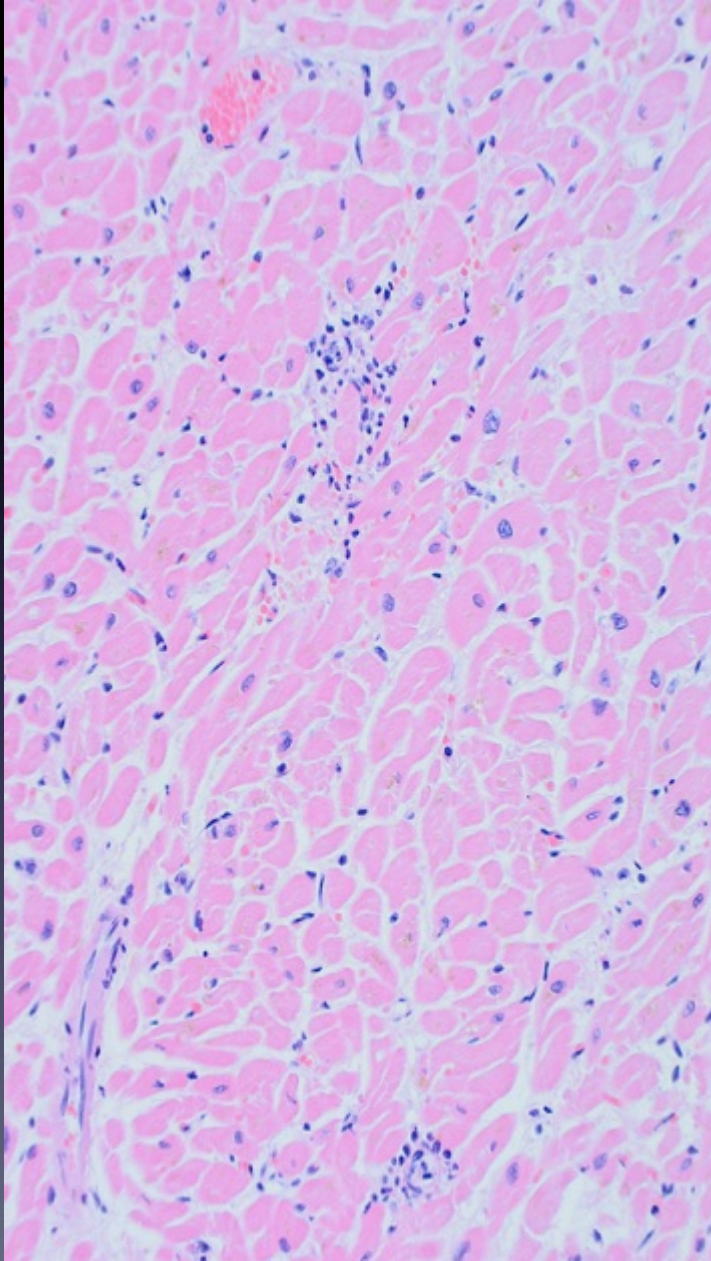
Biventricular dilatation

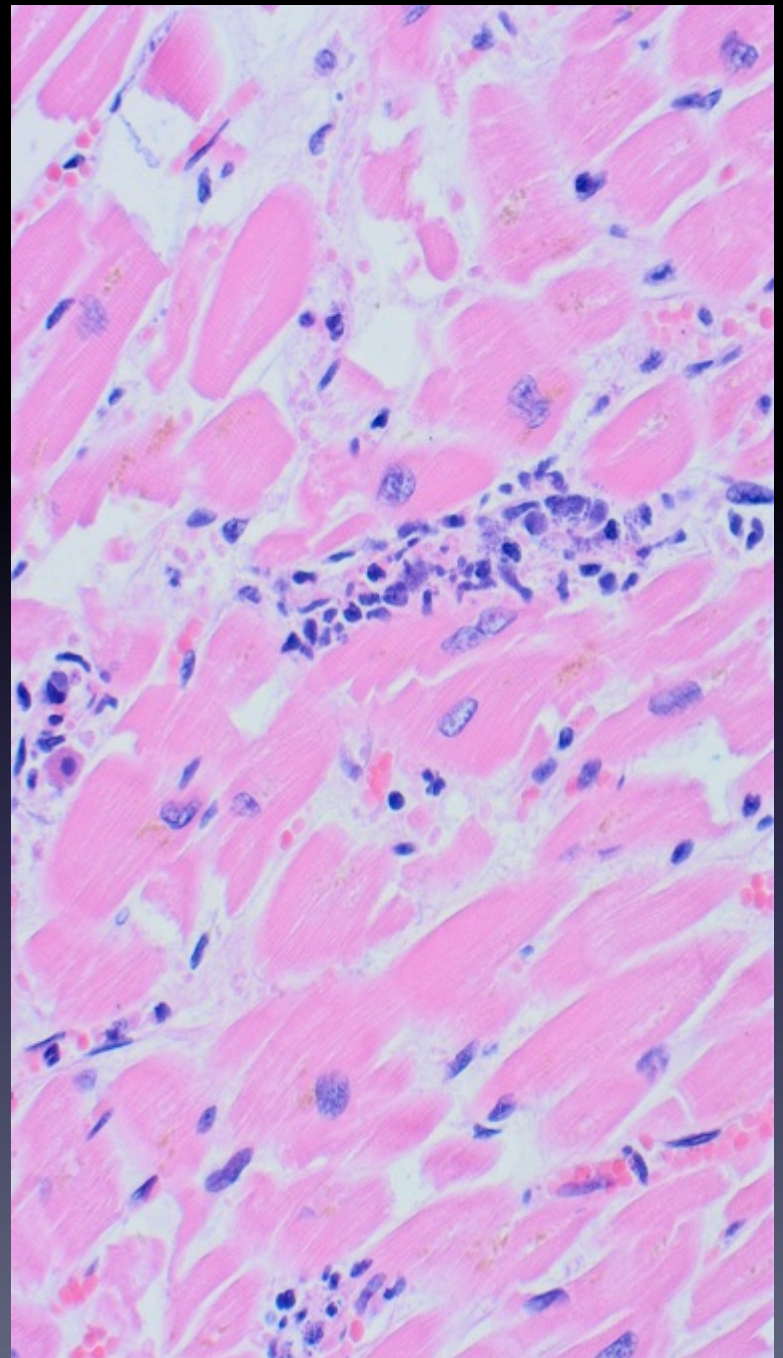
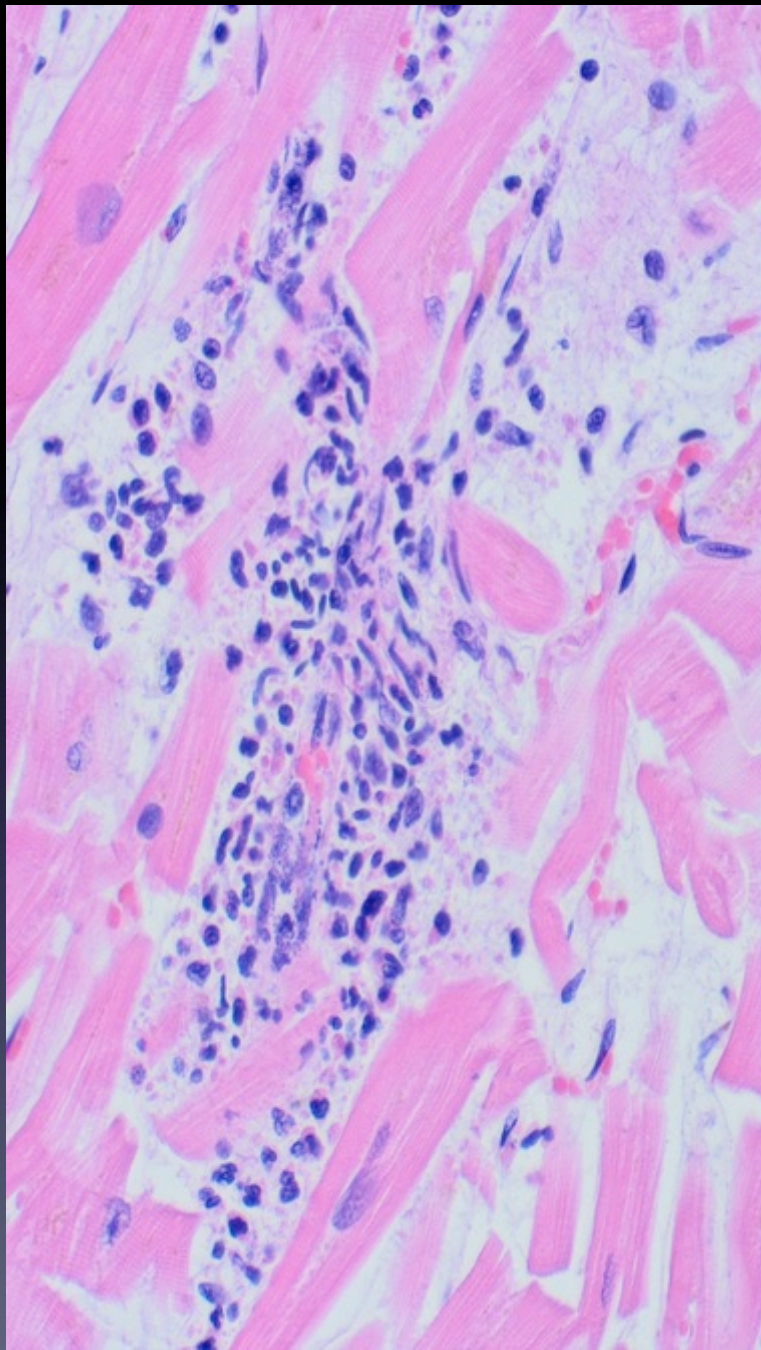
No areas of fibrosis

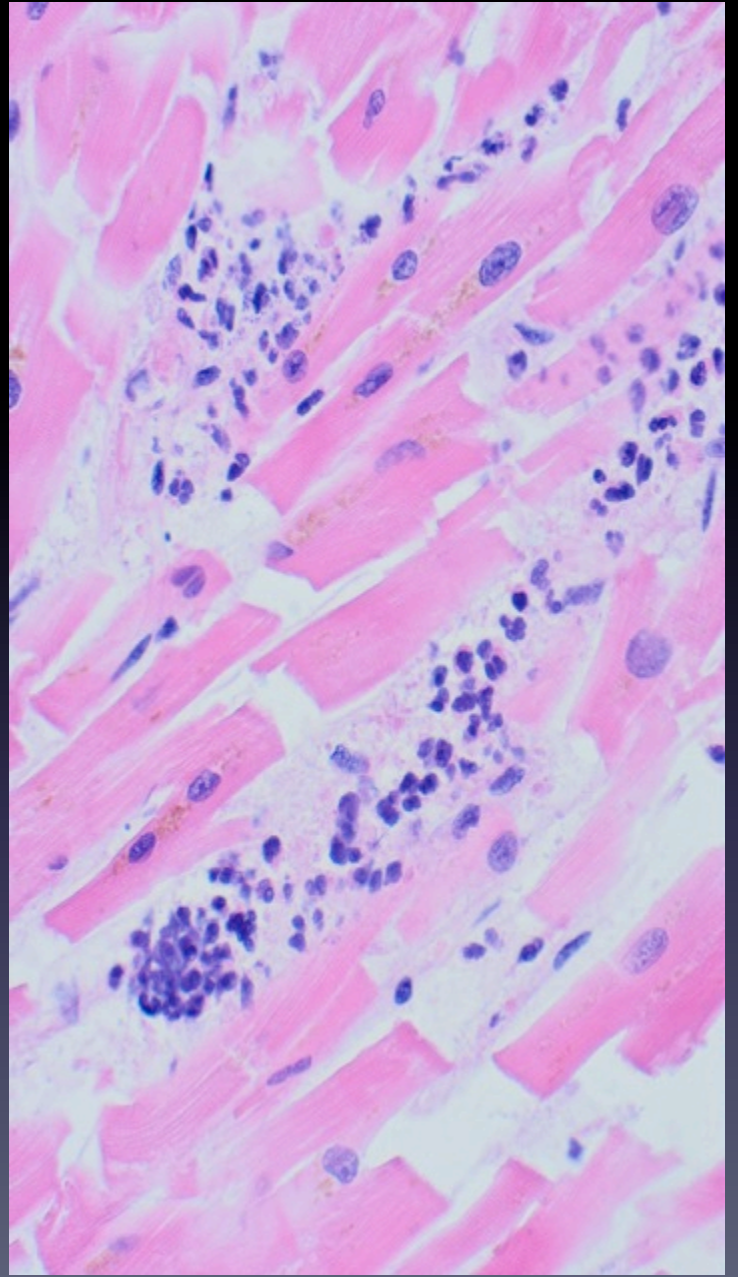
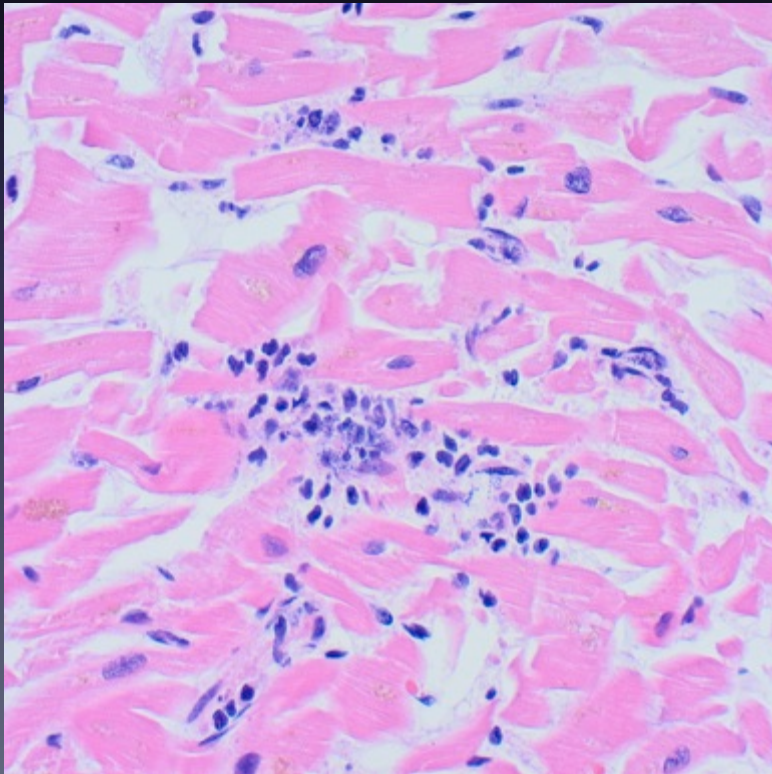
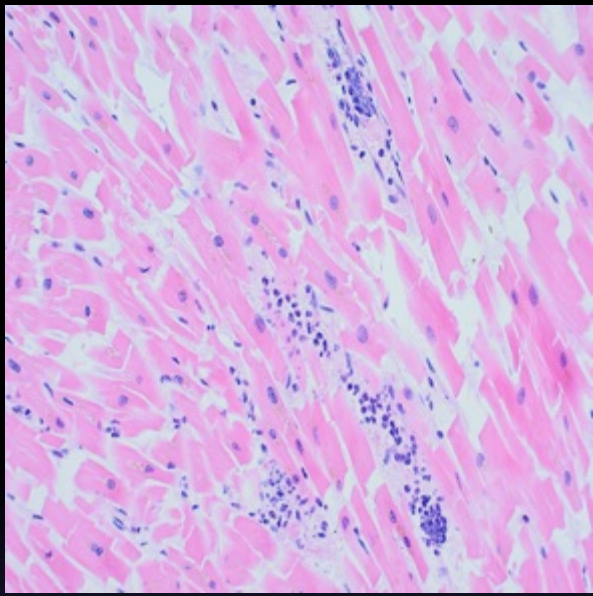
Valves ok.

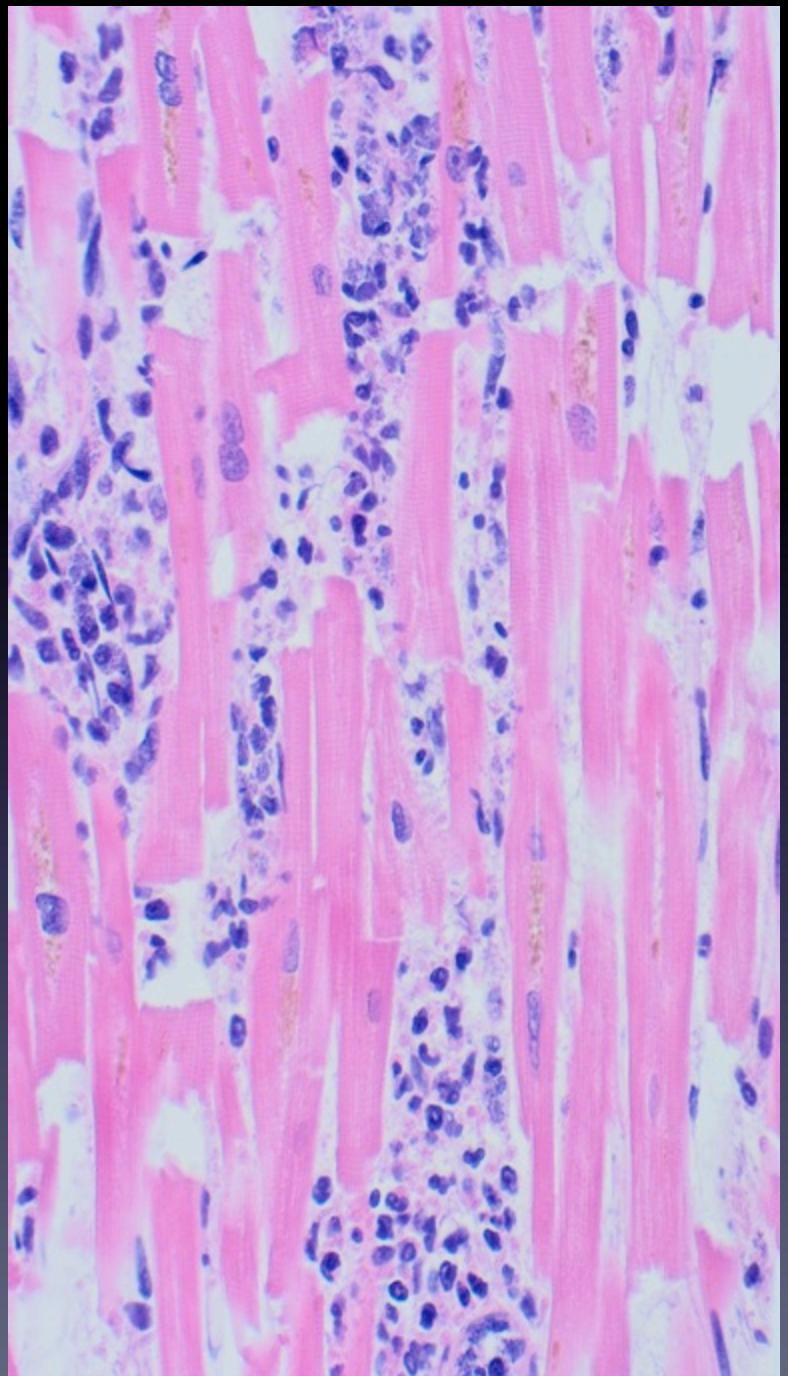
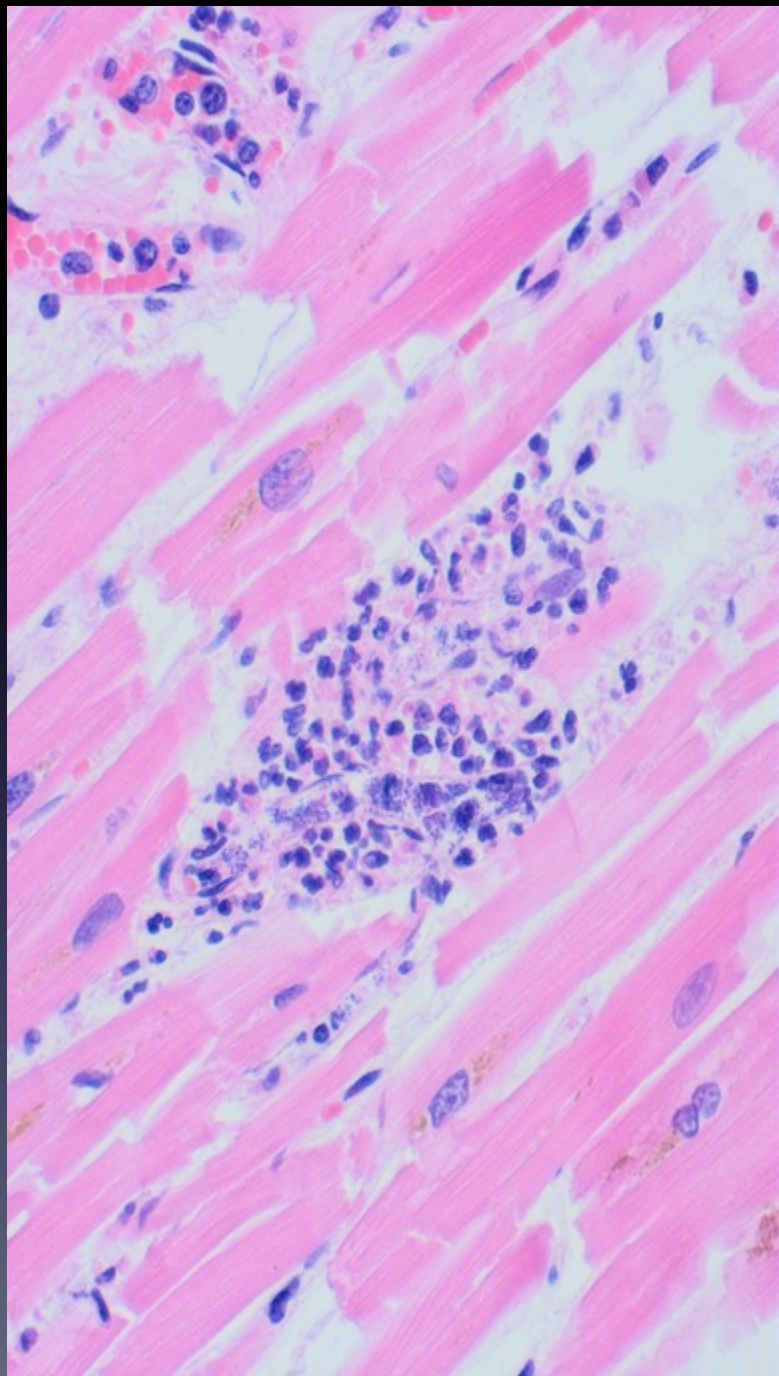
Resp / CNS/ Abdo – nil to note. No evidence of infection or sepsis.

Histology of the heart









Thoughts.....

CPR changes?

Myocarditis ? Viral PCR ?

Multifocal ischaemia ?

Sepsis ? - gram stains ? PM related.